

EXHIBIT B



Search bar containing 'immunophenotyping of acute lymphobla' and a magnifying glass icon.

All **Images** Maps Shopping More Settings Tools

About 4 results (0.82 seconds)




Image size: 1184 x 972

No other sizes of this image found.

Best guess for this image: **immunophenotyping of acute lymphoblastic leukemia**

Immunophenotyping of acute lymphoblastic leukemia using ... - NCBI

<https://www.ncbi.nlm.nih.gov/pubmed/18712674>

by LA Al Gwaiz - 2008 - Cited by 7 - Related articles

Histol Histopathol. 2008 Oct;23(10):1223-8. doi: 10.14670/HH-23.1223. Immunophenotyping of acute lymphoblastic leukemia using immunohistochemistry in bone marrow biopsy specimens. Al Gwaiz LA(1), Bassioni W. Author information: (1)Section of Hematopathology, Department of Pathology, College of Medicine, King ...

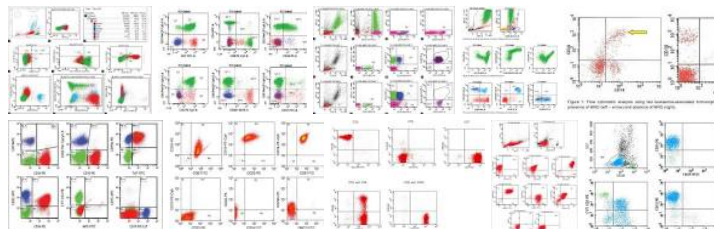
Diagnosis and Subclassification of Acute Lymphoblastic Leukemia

<https://www.ncbi.nlm.nih.gov/pmc/articles/PMC4235437/>

by S Chiaretti - 2014 - Cited by 41 - Related articles

Jump to Diagnostic **Immunophenotype** - Immunophenotyping by means of multi-channel flow cytometry (MFC) has become the standard procedure for ALL diagnosis and subclassification, and was also developed as useful tool for the detection and monitoring of minimal residual disease (MRD, reviewed elsewhere in ...

Visually similar images



Report images

Pages that include matching images

Minimal residual disease program for acute lymphoblastic leukemia at ...

www.jahjournal.org/article.asp?issn=1658-5127;year=2016;...

by NK Amra - 2016 - Related articles

1673 x 1281 - Apr 25, 2016 - Figure 1: Dotplots illustrating sequential selective gating on day 8 bone marrow aspirate on a sample bone marrow of a patient with acute lymphoblastic leukemia demonstrating a leukemia aberrant immunophenotype pattern consisting of CD19+/CD10+/CD34+/CD58 + leukemic blasts. The top row ...

Issue 1 (January-March) - Journal of Applied Hematology : Table of ...

www.jahjournal.org/showBackIssue.asp?issn=1658-5127;year=2016;...

1673 x 1281 - Minimal residual disease program for acute lymphoblastic leukemia at Dhahran Health Center, p. 17. Nasir Khalid Amra, Salwa Shaberdeen Sheikh, Basel A Abushullaih, Nafeesa A Al-Faris, Adil A Al-Khatti, Huda H Al-Sayed DOI:10.4103/1658-5127.181113. Background and Objectives: Minimal residual disease (MRD) ...

Long Island City, New York - From your Internet address - Use precise location - Learn more

Help Send feedback Privacy Terms



Search bar containing 'cbc with differential' and a magnifying glass icon.

All Images Maps Shopping More Settings Tools

About 25,270,000,000 results (0.72 seconds)




Image size: 1048 x 734. No other sizes of this image found.

Best guess for this image: cbc with differential

CBC - Clinical: CBC with Differential, Blood - Mayo Medical Laboratories

https://www.mayomedicallaboratories.com/test-catalog/Clinical+and.../9109

CBC : RBCs, WBCs, and platelets are produced in the bone marrow and released into the peripheral blood. The primary function of the RBC is to deliver oxygen to tissues. WBCs are key components of the immune system. Platelets play a vital role in blood clotting. Mean corpuscular volume (MCV) is a measure of the size ...

005009: Complete Blood Count (CBC) With Differential | LabCorp

https://www.labcorp.com/test-menu/.../complete-blood-count-cbc-with-differential

Hematocrit; hemoglobin; mean corpuscular volume (MCV); mean corpuscular hemoglobin (MCH); mean corpuscular hemoglobin concentration (MCHC); red cell distribution width (RDW); percentage and absolute differential counts; platelet count (RBC); red cell count; white blood cell count (WBC) ...

Complete blood count

Medical exam


A complete blood count, also known as a complete blood cell count, full blood count, or full blood exam, is a blood panel requested by a doctor or other medical professional that gives information about ... Wikipedia

MedlinePlus: 003642

People also search for: Erythrocyte sedimentation rate, MORE

Feedback

Visually similar images



Report images

Pages that include matching images

Case 726 --Hematopathology Case



path.upmc.edu/cases/case726.html

644 x 457 - Three days later, he returned to the Emergency Room with shortness of breath, cough, and left-sided pleuritic chest pain. A CT scan of the chest showed left upper lobe lung consolidation consistent with pneumonia, a moderate left pleural effusion, and giant bullous emphysema. The patient's CBC and differential indicate a ...

What is cbc platelet no differential - The best thing in our life is love



edusl.info/badace/what-is-cbc-platelet-no-differential.php

644 x 457 - Feb 18, 2018 - differential platelet what cbc is no. Common conditions under which a specimen will be rejected. Indur may advise you to follow up with your doctor after reviewing the results of your blood test. Hematocrit A Complete Blood Count with Differential also includes a hematocrit - a measure of the density of red ...

Cbc with diff analysis essay - Dissertation Results - Online Essay ...



www.unitrade-bg.com/zom/.../cbc+with+diff+analysis+essay-5028

644 x 457 - Dec 19, 2017 - *CBC = complete blood cell count; Complete Blood Count CBC Test Sample Complete You might get a CBC as part of your yearly check-up. The complete blood count CBC is a test that evaluates the cells that circulate in blood. Interpreting the Complete Blood Count and Differential. When you get your ...

cbc no differential test x--x.us 2018



x--x.us/?p=5889

644 x 457 - Theme of the day:cbc no differential test. IMAGE TAG: cbc differential no test differential no no differential differential test test no New Year 2018 · 123456789 10111213141516171819202122232425262728293031323334353637383940 414243444546474849505152535455565758596061626364656667686970.

Cbc With Differential Related Keywords & Suggestions - Cbc With ...



www.keywordlister.com/Y2JjIHdpdGggIGRpZmZlcmVudGlibA/

644 x 457 - These are some of the images that we found within the public domain for your " Cbc With Differential" keyword. These images will give you an idea of the kind of image(s) to place in your articles and websites. You can always use one of these images but please respect the copyright of the owner. We have provided the ...